

Parasitic Enteropathogens 2

Clinical Parasitology

FACTM Pt 1

Tim Inglis

Division of Microbiology & Infectious Diseases,
PathWest Laboratory Medicine, WA



Enteric infection series

- EI 1 Clinical Tropical Medicine
- EI 2 Clinical Parasitology 1
- EI 3 Clinical Parasitology 2
- EI 4 Travel & Expedition Medicine



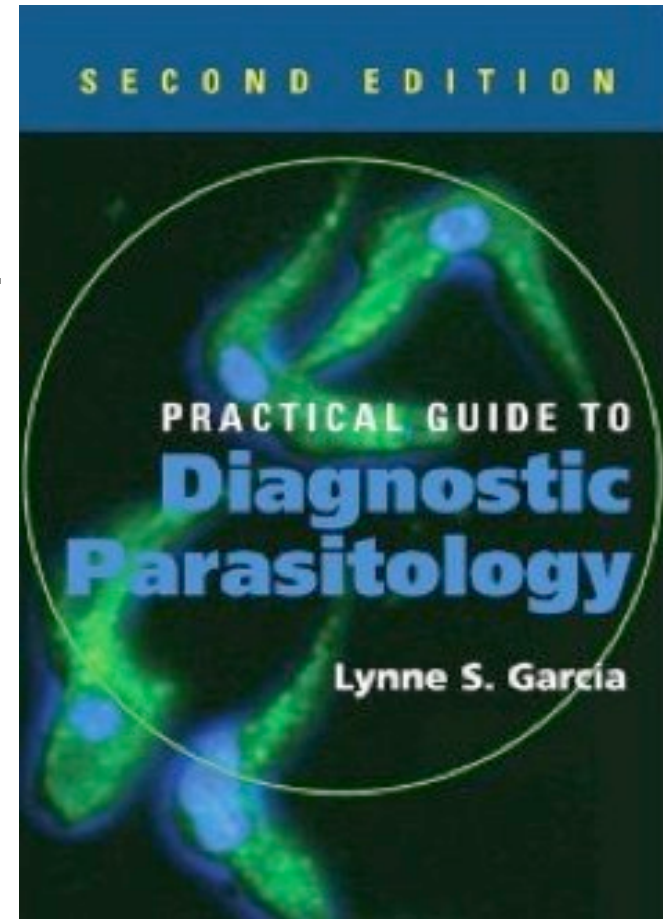
Study materials

Practical Guide to Diagnostic Parasitology.
2nd Edition, Garcia LS. 2009. ASM Press.

- FACTM bookshelf
- FACTM study notes
- Blog – clinical cases
- Self-assessment questions

Blog <http://micrognome.priobe.net>

Web www.priobe.net



Enteric helminths

Parasite	group	Infective stage
<i>Ascaris lumbricoides</i>	nematode	egg
Hookworms	nematode	larva
<i>Strongyloides stercoralis</i>	nematode	Larva
<i>Taenia solium</i>	cestode	Egg
<i>Taenia saginata</i>	cestode	Egg
<i>Diphyllobothrium latum</i>	cestode	Egg
<i>Fasciola hepatica</i>	trematode	Metacerceria
<i>Paragonimus westermanii</i>	trematode	Metacerceria
<i>Clonorchis sinensis</i>	trematode	Metacerceria
<i>Fasciolopsis buski</i>	trematode	Metacerceria




Enteric helminths

Parasite	group	Infective stage
<i>Ascaris lumbricoides</i>	nematode	egg
Hookworms	nematode	larva
<i>Strongyloides stercoralis</i>	nematode	Larva
<i>Taenia solium</i>	cestode	Egg
<i>Taenia saginata</i>	cestode	Egg
<i>Diphyllobothrium latum</i>	cestode	Egg
<i>Fasciola hepatica</i>	trematode	Metacerceria
<i>Paragonimus westermanii</i>	trematode	Metacerceria
<i>Clonorchis sinensis</i>	trematode	Metacerceria
<i>Fasciolopsis buski</i>	trematode	Metacerceria



Ascaris lumbricoides



Egg: c75µm long with roughened (mamillated) surface and if fertile, embryo inside

Stages

- Eggs - infective
- Larva - tissue invasive, migrate to bloodstream

Key features

- Adult sometimes visible on X-ray
- Eggs have knobby coat
- High work burden possible
- May cause nutritional impairment
- Possible association with TB susceptibility
- Albendazole, Ivermectin



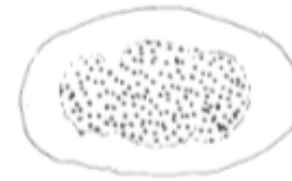Adult worm: (nematode) with smooth external surface & curved body, 15-35cm



Hookworms

Key features

- Smooth walled egg containing larvae
- Mouthparts of adult
- *Necator americanus* & *Ancylostoma duodenale* (both present in SE Asia)
- Intestinal symptoms, pneumonitis, anaemia
- Infection by larval penetration of skin
- Microscopy of faecal smear
- Possible protection v asthma & malaria but increased TB and HIV susceptibility



Egg: c 60µm long, clear space between thin shell and developing embryo



Adult hookworm mouthparts: (*A. duodenale*) showing teeth



Adult hookworm mouthparts: (*A. duodenale*) showing cutting plates



Strongyloides stercoralis

Key features

- Rhabditiform larvae in stool
- Filariform larvae infect by penetrating skin

Biology

- Nematode
- Various routes to duodenum including lungs
- Hyperinfection syndrome
- HIV/AIDS patients



Larvae (rhabditiform stage):
seen in faeces, usually with
no eggs, short mouth
opening



Taenia solium

Biology


- Eggs, containing 6 hooked embryo
- Larvae - cysticerci
- Adult tapeworm comprising scolex and chain of strobila or proglottids

Infection

- Minimal symptoms of adult
- Cysticerci may cause adult onset epilepsy
- Adult work on ingestion of larvae
- Ingested eggs lead to penetration of intestine by embryo

Antiparasitic agents

- Praziquantel, albendazole



Egg: 31-43µm. *T. solium* eggs cannot be distinguished microscopically from *T. saginata*. Thick, striated shell containing 6 hooked embryo.



Clonorchis sinensis

Biology

- Adult worm in liver, lungs
- Infective stage = metacercariae

Infection

- Complications of infection of biliary tract
- Faecal smear but flotation method doesn't work well

Antiprotozoal agents

- Praziquantel
- albendazole



Egg: 28-35 μ m long. Trematode. shouldered operculum at one end and embryo inside. Small button or tail may be seen at other end.



Further issues

Other enteropathogenic helminths

- Fasciola hepatica
- *Paragonimus westermanii*

Diagnostic support

- Faecal concentration methods
- Limited role for serology
- PCR assays

Antiprotozoal agents

Praziquantel, Ivermectin, Nitazoxanide

