

Parasitic Enteropathogens 1

Clinical Parasitology

FACTM Pt 1

Tim Inglis

Division of Microbiology & Infectious Diseases,
PathWest Laboratory Medicine, WA



Enteric infections series

- EI 1 Clinical Tropical Medicine
- EI 2 Clinical Parasitology 1
- EI 3 Clinical Parasitology 2
- EI 4 Travel & Expedition Medicine



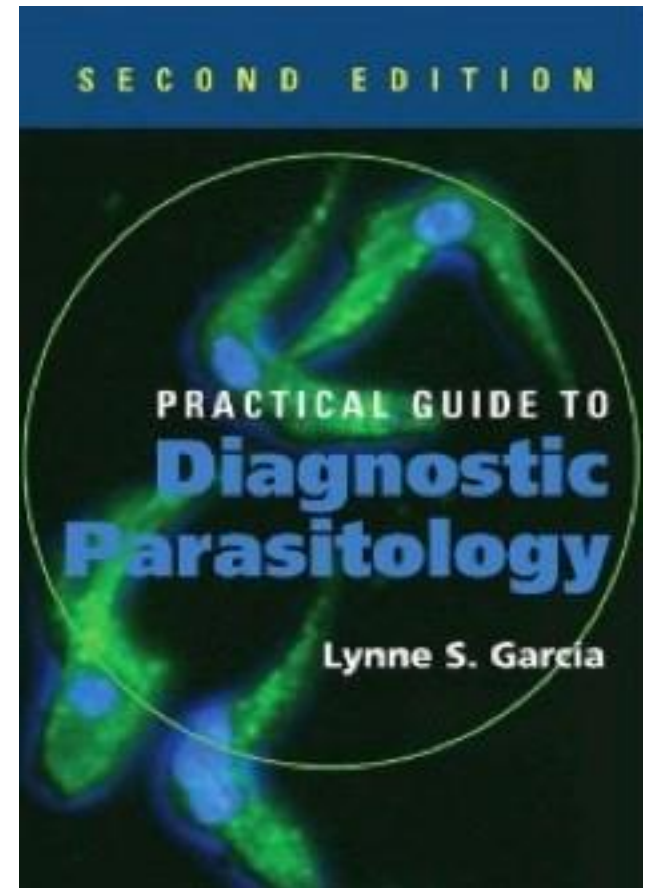
Study materials

Practical Guide to Diagnostic Parasitology.
2nd Edition, Garcia LS. 2009. ASM Press.

- FACTM bookshelf
- FACTM study notes
- Blog – clinical cases
- Self-assessment questions

Blog <http://micrognome.priobe.net>

Web www.priobe.net



Enteric protozoa

Parasite	group	pathogenic
<i>Entamoeba histolytica</i>	Amoeba	Yes
<i>Entamoeba dispar</i>	Amoeba	No
<i>Entamoeba coli</i>	Amoeba	No
<i>Blastocystis hominis</i>	Amoeba	Sometimes
<i>Giardia lamblia</i>	Flagellate	Yes
<i>Balantidium coli</i>	Ciliate	Yes
<i>Cryptosporidium</i>	Sporozoan	Yes
<i>Cyclospora cayetanensis</i>	Sporozoan	Yes
<i>Cytoisospora belli</i>	Sporozoan	Yes
<i>Microsporidia</i>	Sporozoan	Yes



Enteropathogenic protozoa

Parasite	group	pathogenic
<i>Entamoeba histolytica</i>	Amoeba	Yes
<i>Entamoeba dispar</i>	Amoeba	No
<i>Entamoeba coli</i>	Amoeba	No
<i>Blastocystis hominis</i>	Amoeba	Sometimes
<i>Giardia lamblia</i>	Flagellate	Yes
<i>Balantidium coli</i>	Ciliate	Yes
<i>Cryptosporidium</i>	Sporozoan	Yes
<i>Cyclospora cayetanensis</i>	Sporozoan	Yes
<i>Cytoisospora belli</i>	Sporozoan	Yes
<i>Microsporidia</i>	Sporozoan	Yes



Entamoeba histolytica

Stages

- cyst - infective
- trophozoite - tissue invasive

Key features

- cyst size
- chromatin pattern
- chromatoid bodies
- glycogen inclusion
- ingested erythrocytes



Entamoeba histolytica

Diseases

- Amoebic dysentery, colitis, amoeboma
- Amoebic liver abscess
- Skin & other infections

Diagnostic tools

- Faecal sample x3 in 10d
 - trichrome stained, āgen, PCR
- serology
- Abscess contents

Antiprotozoal agents

- Metronidazole, Tinidazole
- Paromomycin, Diloxanide furoate



Blastocystis hominis

Key features

- cyst size
- chromatin pattern

Stained faecal smear

Often indication of other enteropathogen

Role in disease controversial

Multiple spp by PCR genotyping

Diarrhoea, vomiting, stomach cramps

Nitazoxanide x3d, Metronidazole x1



Giardia lamblia

Key features

- cyst size
 - central axostyle
- trophozoite

Biology

- Flagellate
- Duodenal mucosa
- Cyst formation in jejunum
- Possible animal reservoirs



Giardia lamblia

Infection

- Diarrhoea, epigastric pain, flatulence, fat malabsorption

Diagnostic support

- Faecal smear, EIA
- Duodenal aspirate, biopsy

Antiprotozoal agents

- Tinidazole, Metronidazole
- Paromomycin



Cryptosporidium

Biology

- *C. parvum* & *C. hominis*
- Sporozoan, intracellular, parasitophorous vacuole, mainly jejunum, autoinfective cycle

Infection

- Diarrhoea, watery or frothy stool, abdominal cramps, nausea, limited period in immunocompetent
- Faecal smear, modified acid fast stain
- Prolonged in HIV/AIDS

Antiprotozoal agents

- Nitazoxanide, little if any effect



Cyclospora cayetanensis

Biology

- coccidian, unsporulated cysts, jejunum enterocytes

Infection

- Diarrhoea, frequent stools, nausea, short lived but relapses, fever, myalgia, D-xylose malabsorption
- Faecal smear, modified acid fast stain

Antiprotozoal agents

- Co-trimoxazole, Nitazoxanide



Further issues

Other enteropathogenic protozoa

- Microsporidia, *Cytoisospora belli*

Diagnostic support

- Faecal concentration methods
- EIA
- PCR assays

Antiprotozoal agents

- Emerging resistance
- Nitazoxanide



Enteric infections series

- EI 1 Clinical Tropical Medicine
- EI 2 Clinical Parasitology 1
- EI 3 Clinical Parasitology 2
- EI 4 Travel & Expedition Medicine

